

Pituitary apoplexy—a rare and unusual complication following viper bite

Ritwika Majumdar¹, Lina Mukherjee¹, Uttam Biswas², Chanchal Kumar Jana¹

¹Department of Medicine, R G Kar Medical College, West Bengal, Kolkata, India.

²Department of Medicine, Burdwan Medical College, West Bengal, Kolkata, India.

Correspondence to: Uttam Biswas, E-mail: druttambiswas@gmail.com

Received July 7, 2016. Accepted August 7, 2016

Abstract

Envenomation resulting from snake bite is an important public health problem in tropical countries like South Asia and throughout Indian subcontinent. Snake bite is associated with myriad of complications that can be life threatening. Here, an 18 year old woman who was bitten by Russell's viper was reported and was treated with antivenom, other medications and supportive therapy like haemodialysis. Although the patient recovered from the acute effects, patient continued to remain unwell, developed amenorrhea, loss of axillary and pubic hair and was investigated and diagnosed 4 months later with hypopituitarism. Replacement started with essential hormones such as oral ethinyl estradiol/norgestrel and Levo- thyroxine. In this case report, it is discussed why it is important to evaluate for pituitary function in every patient who sustained a Russell's viper bite.

KEY WORDS: Russell's viper, hypopituitarism, partially empty sella

Introduction

Snake bites are well known medical emergencies in many parts of the world especially in tropical countries, including India. Nearly, of the 216 species of snake identifiable in India 52 are known to be poisonous. The major families of snakes in India are elapidae which includes common cobra, king cobra and common krait; viperidae includes Russell's viper, saw scaled viper and pit vipers and hydrophiidae (sea snake). Different species of snake bite are associated with different clinical features, although there may be considerable overlap in presentations. To diagnose the species of snake responsible for the bite for optimal clinical management, a syndromic approach have been developed by world health organization (WHO). Snake bites are associated with various

complications. Here, hypopituitarism in a patient of following Russell's viper bite is discussed.

Case Report

An 18 year old female patient was admitted to our hospital with the history of being bitten by a Russell's viper on the right foot while returning from the fields in the evening. Initially the patient noticed only mild pain and swelling at the site of bite but half an hour later she complained of vomiting, headache and weakness for which she was taken to the local hospital. There the patient initially passed red coloured urine once, followed by anuria. The patient was given 10 vials of anti-snake venom (ASV) and was referred to our hospital, after one day stay at local hospital.

The patient, a tall young female, presented to our hospital 36 hours after the incident with engorged neck veins, facial, and pedal edema. There was no pallor, cyanosis, jaundice, clubbing or any lymphadenopathy. There was local swelling at the site of bite which was tender to touch. Her pulse was 108/min regular, blood pressure 124/76 mm of Hg, and respiratory rate was 30/min regular abdominothoracic and shallow. There was mild basal crepitation over both the lung fields. On cardiovascular examination tachycardia was found. Nervous

Access this article online

Website: <http://www.ijmsph.com>

DOI: 10.5455/ijmsph.2017.07072016584

Quick Response Code:



International Journal of Medical Science and Public Health Online 2017. © 2017 Uttam Biswas. This is an Open Access article distributed under the terms of the Creative Commons Attribution 4.0 International License (<http://creativecommons.org/licenses/by/4.0/>), allowing third parties to copy and redistribute the material in any medium or format and to remix, transform, and build upon the material for any purpose, even commercially, provided the original work is properly cited and states its license.

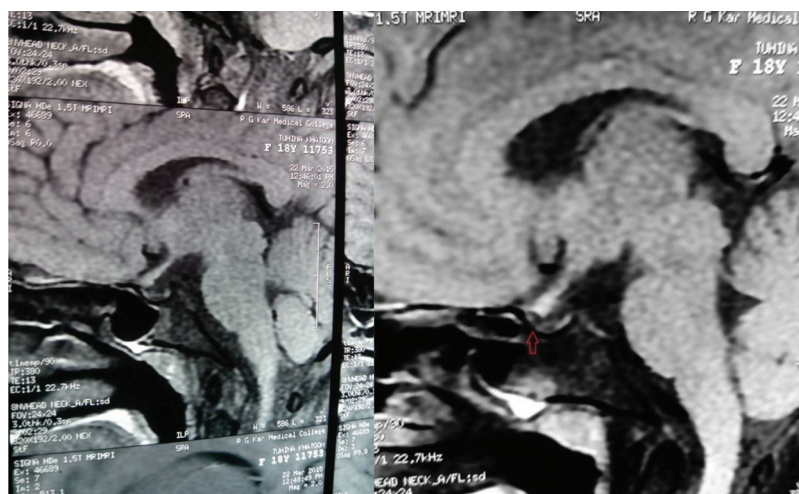


Figure 1: MRI of the brain and pituitary revealed partially empty sella

system and abdominal examination was unremarkable. No bleeding from any site was noted. However, the 20 min whole blood clotting time (WBCT) was prolonged and routine urine examination showed presence of RBCs. ASV was reinstated and few fresh frozen plasmas (FFPs) were transfused.

Investigations revealed hemoglobin to be 9.1 g%, total leucocyte count (TLC) of 14,800 mg%, differentials of 72% neutrophil, 24% lymphocyte, 2% eosinophil and 1% each of basophil and monocyte. The patient's blood urea was 237 mg%, creatinine 8.96 mg%, serum Na^+ 135 mEq/L and K^+ 4 mEq/L. The patient's aPTT, PT and FDP were 24 s, 18 s and 10,000 ng/ml, respectively. Liver function test showed a total bilirubin of 1.2 mg % with slightly elevated liver enzymes and blood for HBsAg, anti-HCV antibody and HIV were negative. USG revealed minimal ascites and mild pericardial effusion. Patient was put on hemodialysis (HD), subsequently 14 HD were done with few units of blood transfusion (BT). In addition IV antibiotics were given along with other supportive measures. The patient's urine output, WBCT, aPTT, PT, Hb, TLC, FDP, blood urea and creatinine were normalized gradually. Patient recovered with our treatment. The patient was subsequently discharged in stable condition after 39 days of admission to our hospital.

The patient presented to our OPD for follow-up 4 weeks later. She then complained of lethargy, mild headache, loss of appetite, and weight loss. Examination of the patient was unremarkable. On the subsequent follow-up visit after 3 months the patient complained of amenorrhea along with her previous complains. Examination of the patient was unremarkable other than sparse axillary and pubic hair and a pulse of 76/min regular and a blood pressure of 100/66 mm of Hg measured in both arms in sitting position. Her supine blood pressure was 100/60 mm of Hg and standing blood pressure after 3 minutes was 88/60 mm of Hg. Urine for pregnancy test was negative. Taking the patient's past history into consideration, a complete blood count, blood urea, serum creatinine, electrolytes, liver

function test, along with serum FT4, TSH, 8 AM serum cortisol, FSH, LH and prolactin was ordered. The reports showed normal counts, and liver and renal function test with serum sodium of 127 mEq/l and K^+ of 5 mEq/l. Blood 8 AM cortisol was 4.70 ng/ml, FT4 and TSH was 0.6 ng/dl (.70–1.48), 2.08 (.35–4.94) micro g/dl, FSH 4.57 (3.5–12.5), LH .73 (2.4–12.6) and prolactin was 12.5 ng/ml (4.7–23.3). MRI (Figure 1) of the brain and pituitary revealed partially empty sella. A diagnosis of post Russell's viper bite pituitary apoplexy was made and the patient was put on oral ethinyl estradiol/norgestrel, hydrocortisone followed by levo-thyroxine replacement. The patient started menstruating after 2 months, lethargy and loss of appetite improved remarkably and currently doing well in subsequent follow-up.

Discussion

The Russell's viper (*Daboia russelii* and *D. siamensis*) is one of the most dangerous snakes in all of Asia including in India, accounting for thousands of death per year. It has a myriad of presentations and complications. Coagulation disorder with or without bleeding manifestations dominates the clinical picture of Russell's viper bite. They are also associated with prominent local signs, hypotension, renal failure and neurological manifestations leading to severe morbidity and mortality. Our patient suffered from both neurotoxic and hematotoxic features immediately after the event and presented 4 weeks later with features of pituitary insufficiency. Our patient developed syndrome 5, as per the criterion given by WHO in 2010.^[1] Hypopituitarism is a complication of Russell's viper bite due to impairment of both pituitary and hypothalamus. Russell's viper bite is known to cause acute and chronic hypopituitarism and diabetes insipidus, perhaps through deposition of fibrin microthrombi and hemorrhage in the pituitary gland resulting from the action of

venom procoagulant enzymes and hemorrhagins. Forty nine cases of hypopituitarism following Russell's viper bite have been described in the literature.^[2] A few cases of hypopituitarism and pituitary necrosis following envenoming by Russell's viper resembling Sheehan syndrome have been reported from various Southeast Asian countries including Sri Lanka, India and Myanmar.^[2-4] Apart from this, unusual complications like myocardial infarction,^[5] ventricular tachycardia,^[6] parotid swelling,^[7] cardiac tamponade, hemoperitoneum may occur following Russell's viper bite.

Conclusion

Diagnosing hypopituitarism in a case of Russell's viper envenomation requires a strong clinical suspicion for this rare complication. Subtle clinical features such as loss of appetite, fatigue and hypotension with normal pulse rate and without any symptom of orthostatic hypotension or hyperpigmentation should raise suspicion of hypoadrenalism. In the background of snake bite such a presentation should raise the suspicion of hypopituitarism.

References

1. Warrell DA. Guidelines for the management of snake bite. 2010 page 56.
2. Antonypillai CN, Wass JA, Warrell DA, Rajaratnam HN. Hypopituitarism following envenoming by Russell's vipers (*Daboia siamensis* and *D. russelii*) resembling Sheehan's syndrome: first case report from Sri Lanka, a review of the literature and recommendations for endocrine management. QJM 2011 Feb ;104(2):97-108.
3. Qnose H, Tamura Y, Fujita H, Nakano T, Shibasaki T. A case of sheehan's syndrome with panhypopituitarism due to the impairment of both the hypothalamus and pituitary. Endo J 2003 Aug;50(4): 415-9.
4. Dharmoal DK, Das AK. Hypopituitarism following snake bite. J Assoc Physician India 1998;(46):322.
5. Dissanayake P, Sellahewa KH. Acute myocardial infarction in a patient with Russell's viper bite. Ceylon Med J 1996;(41):67-8.
6. Thewjitcharoen Y, Poopitaya S. Ventricular tachycardia, a rare manifestation of Russell's viper bite: case report. J Med Assoc Thai 2005;(88):1931-3.
7. Partha Pratim Chakraborty, Rana Bhattacharjee. Bilateral parotid swelling: an unusual complication of viper bite. J Assoc Physician India 2010 July;,(58):460.

How to cite this article: Majumdar R, Mukherjee L, Biswas U, Jana CK. Pituitary apoplexy—a rare and unusual complication following viper bite. Int J Med Sci Public Health 2017;6:429-431

Source of Support: Nil, **Conflict of Interest:** None declared.